

# Photo collections

- Sheep
- Goat
- Camel

## Animal Medicine Department

Faculty of Veterinary Medicine

Benha University

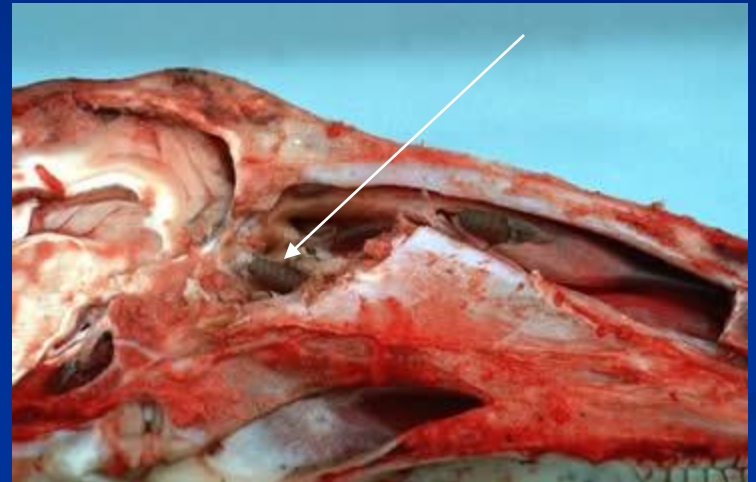
Prof Dr. Mohamed Ghanem

Part 1

# Sheep bot



**Nasal lesion in ostrous ovis infestation**



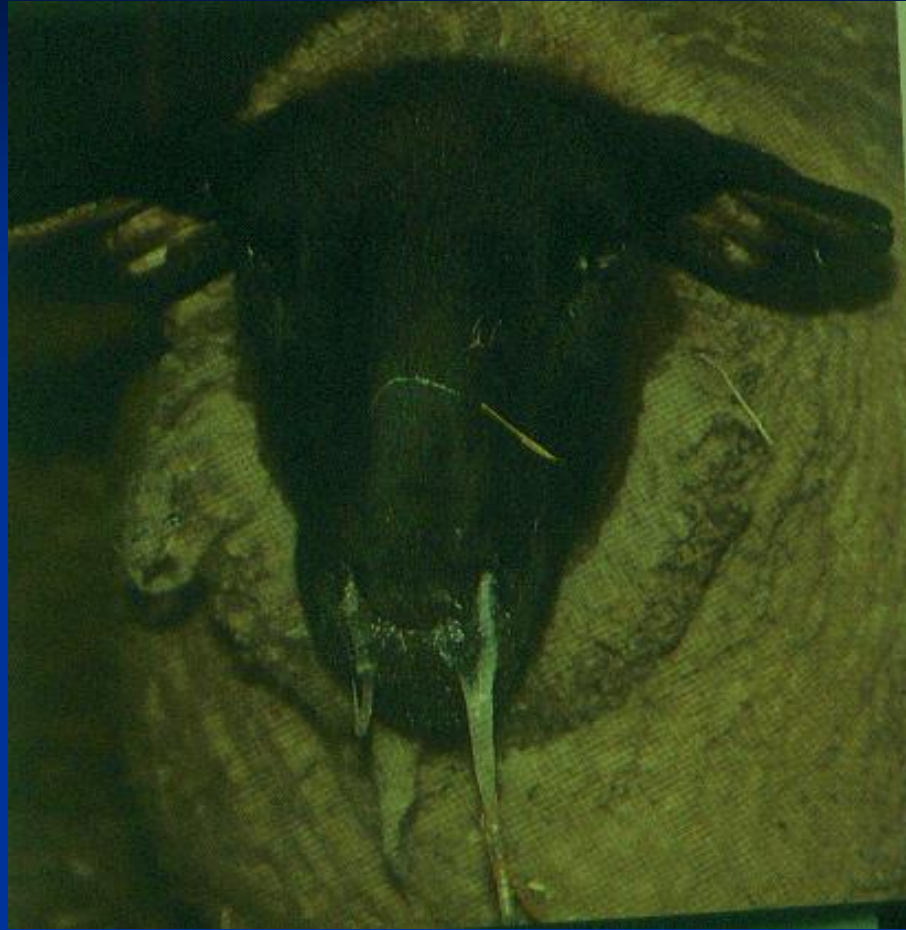**Ostrus Ovis larvae in nasal sinuses**

# photosensitization



Necrosis in the face - nostrils

# Nasal discharge

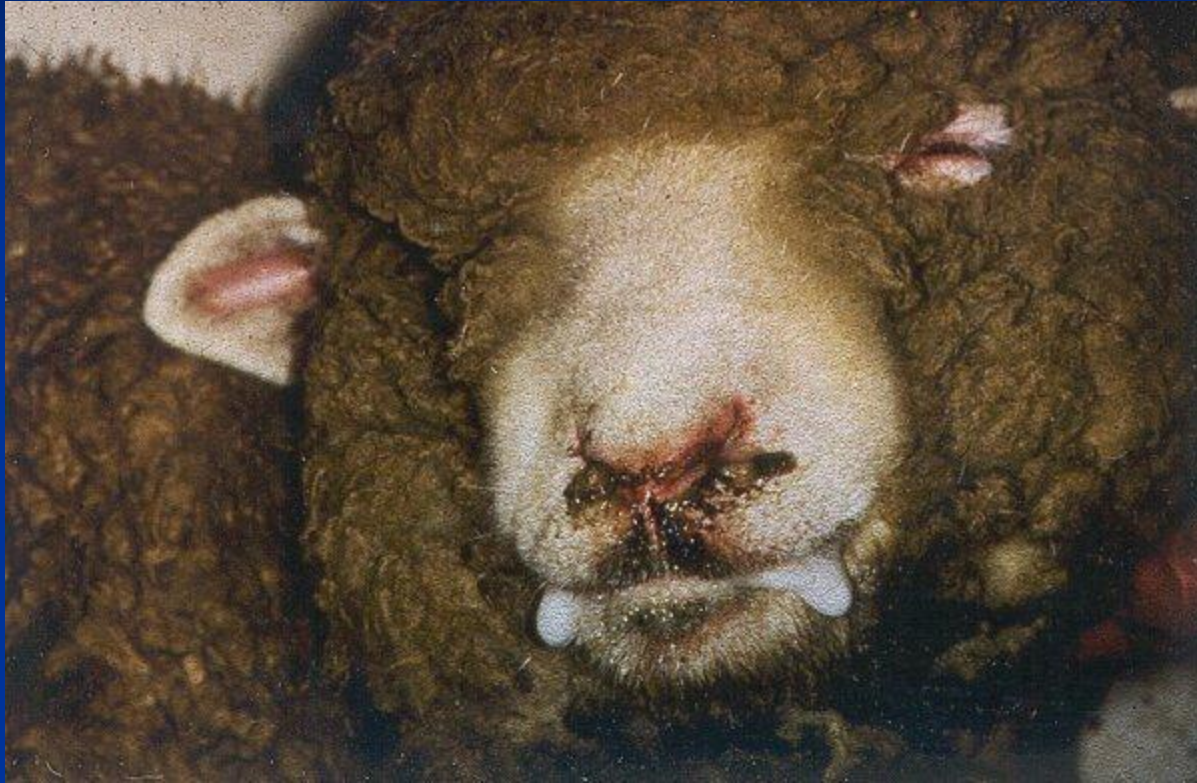

Nasal Discharge (mucopurulent)

# Panting (dyspnea)




# Pneumonia



Frothy from mouth - Pneumonia

# Hypomagnesemia



Frothy from mouth –hypomagnesemia

# Hypocalcemia





# Pregnancy toxemia – ketosis (hypoglycemia)




# Hypomagnesemia – star gazing



# Hypomagnesemia in goats



Convulsions



Grinding on teeth

# Urethral calculi



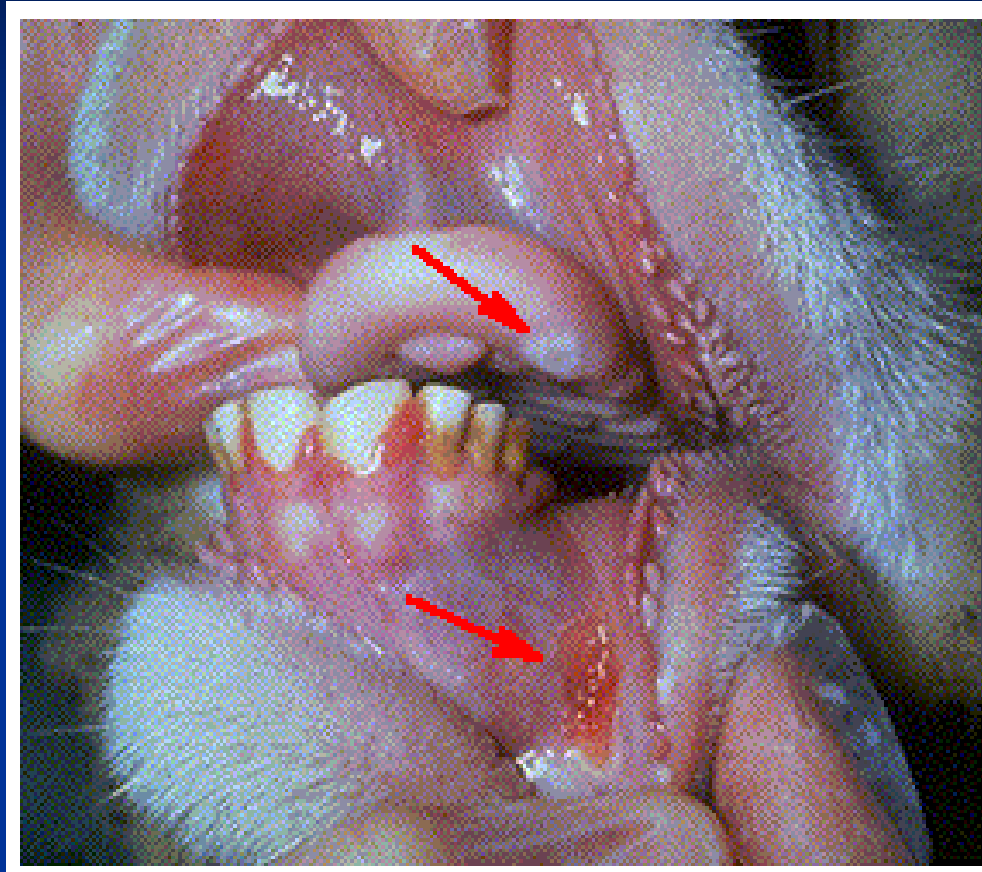
This ram has a stone blockage of his urethra. Notice the marked swelling in the belly and sheath

# Enlarged pres-scapular LN



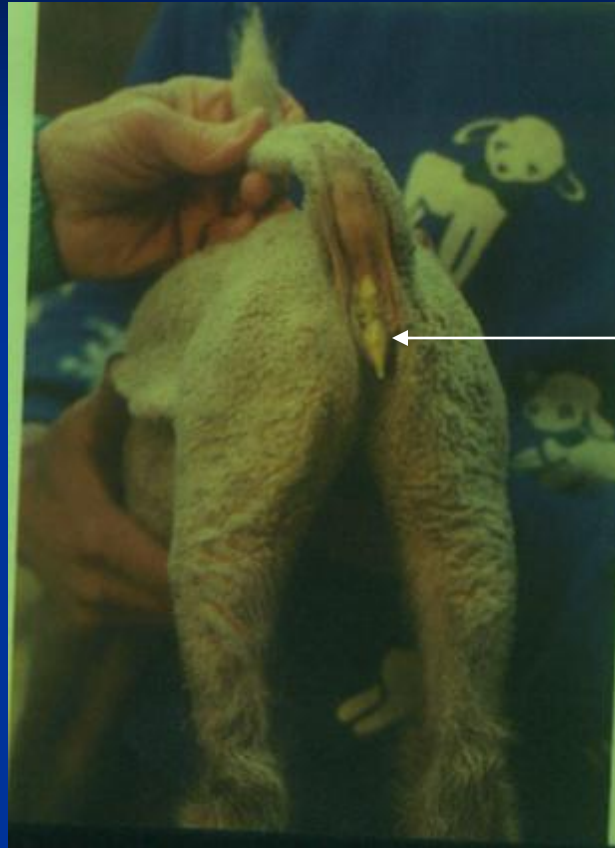Enlargement of pre-scapular LN (caseous lymphadenitis)

# Stomatitis



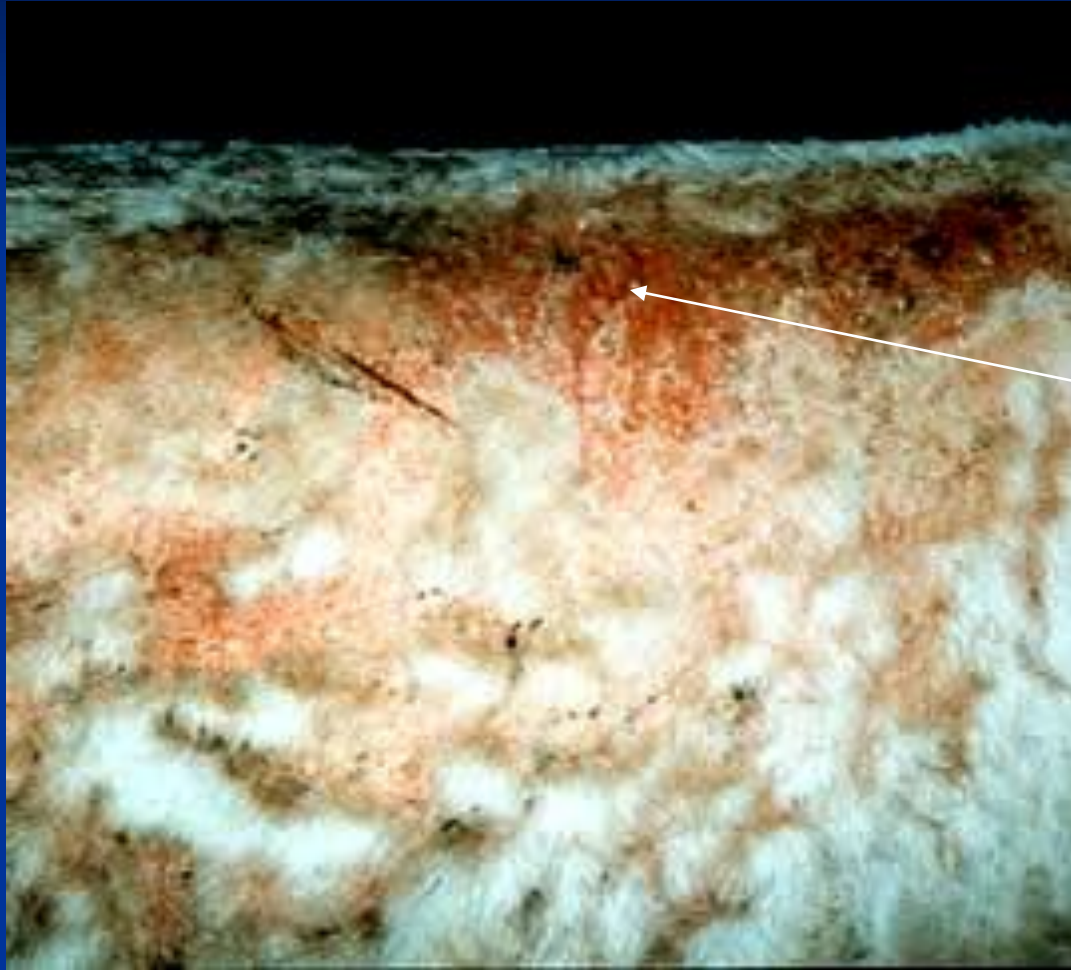
Ulcer in dental pad and gum

# Diarrhea



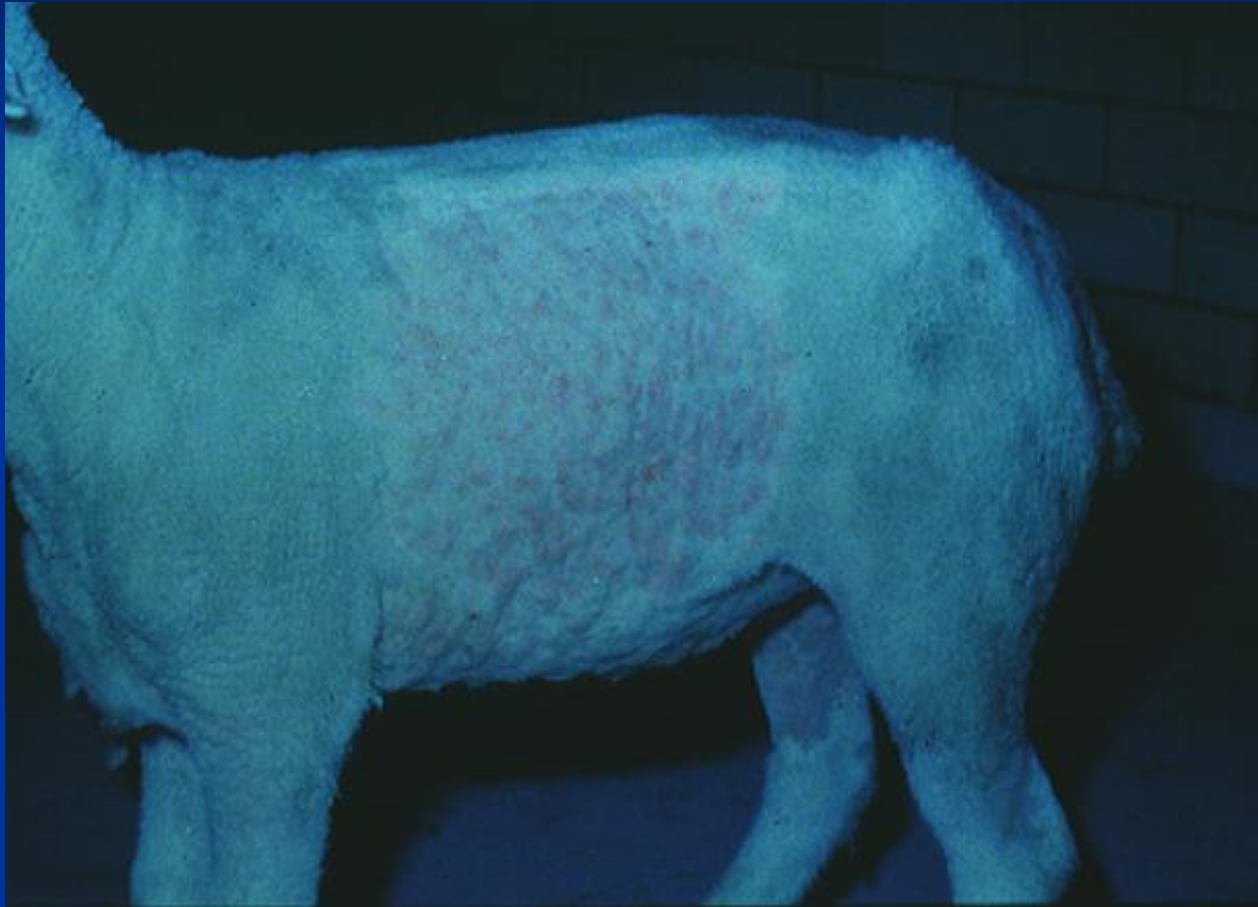Neonatal diarrhoea in a lamb

# Eczema

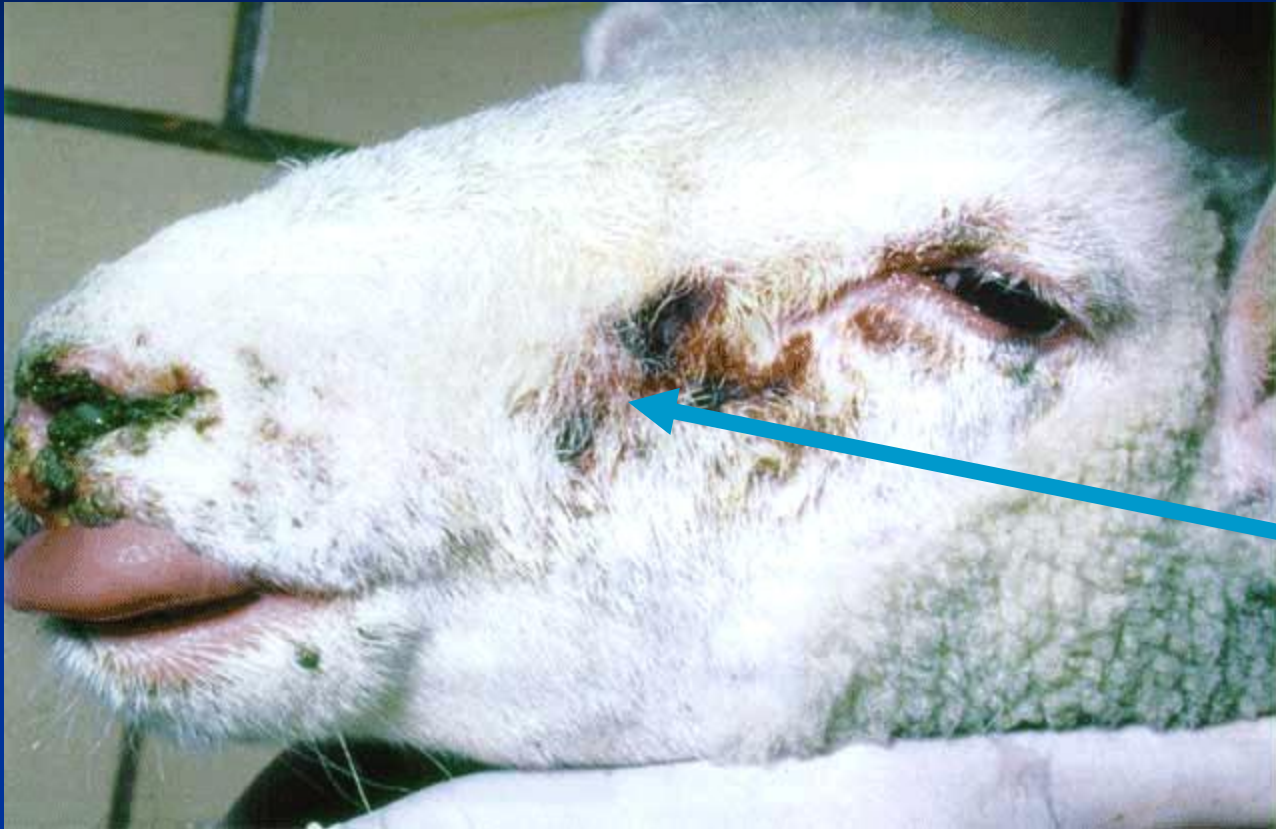



# Papules (pox)

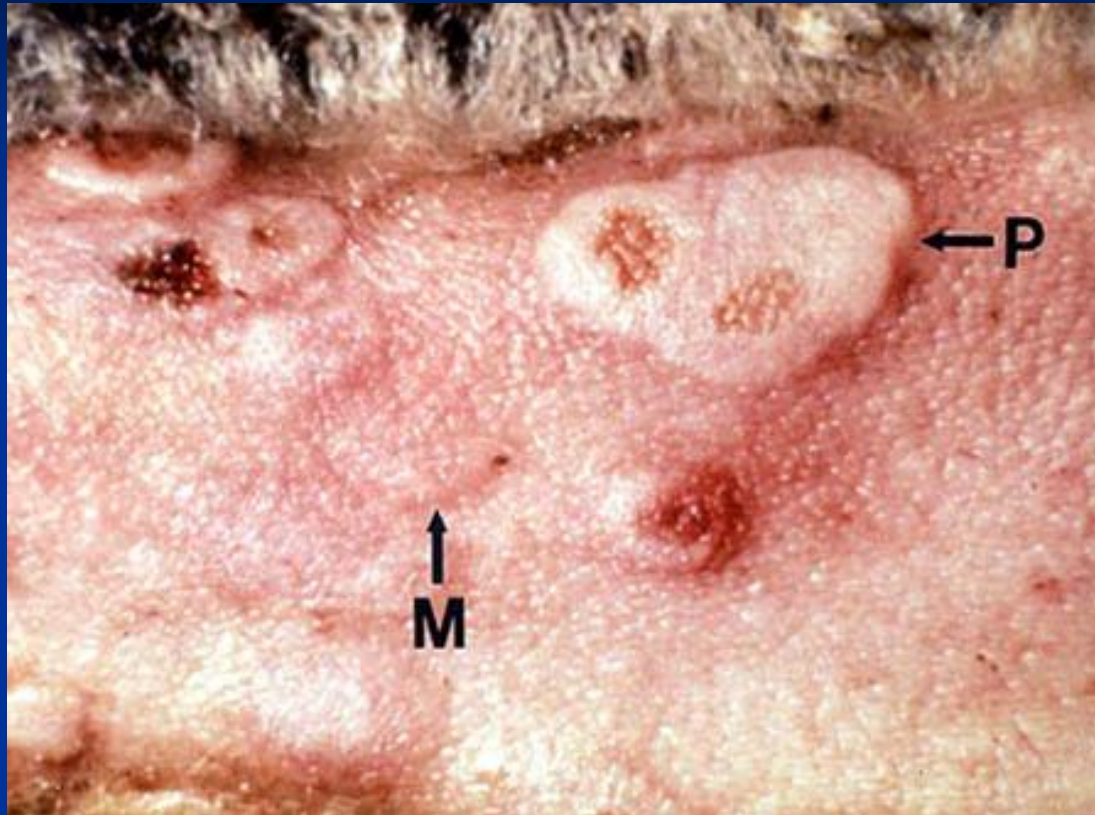


# Dermatitis



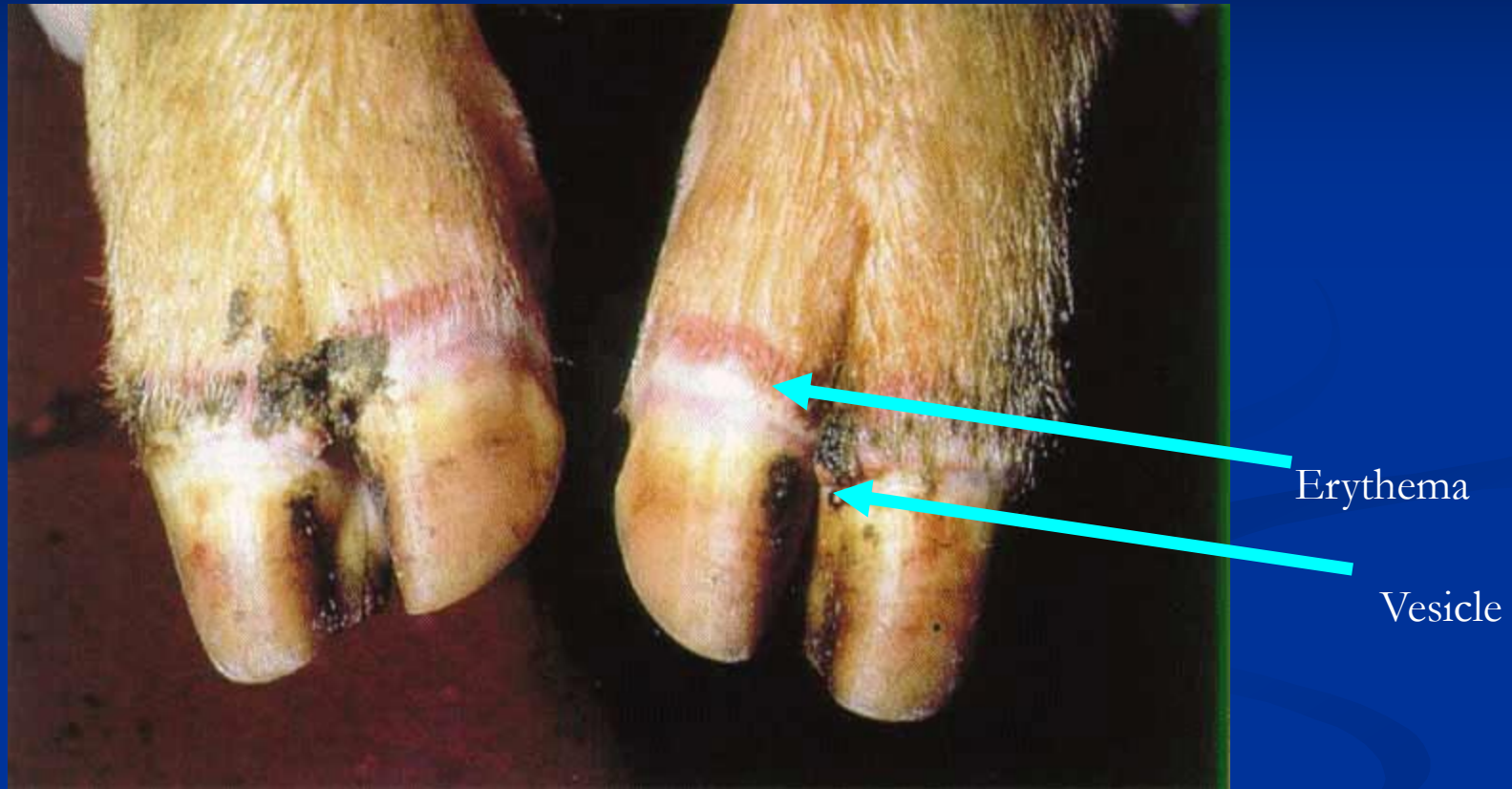Erythema

# Dermatitis under tail



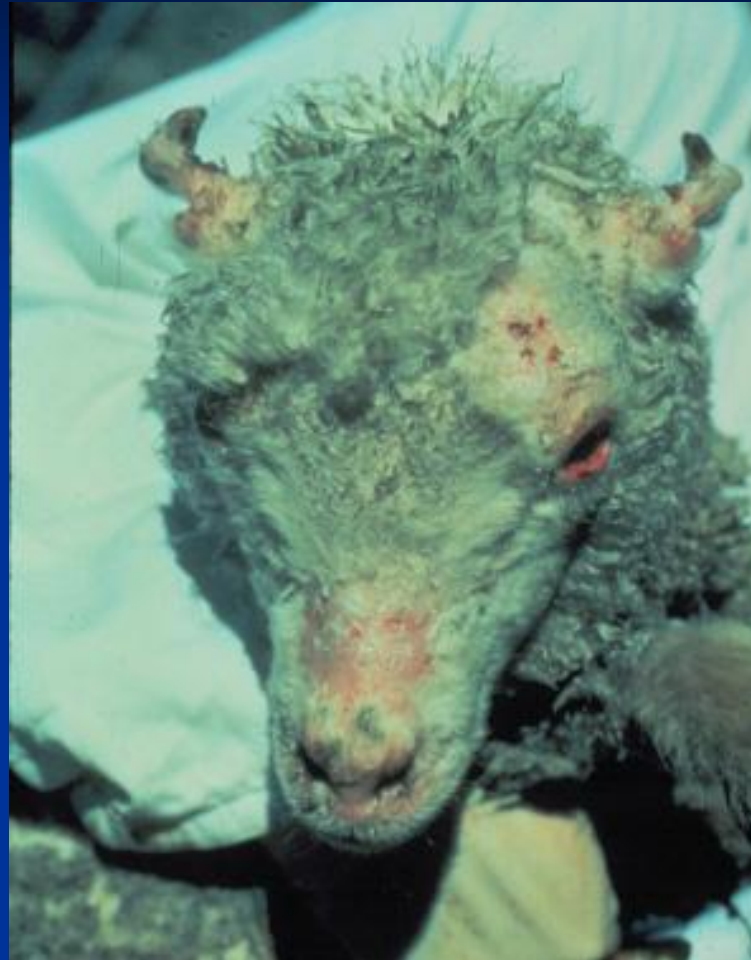Macules and papule under sheep tail

# Dermatitis in sheep



Foot and Mouth disease

# Dermatitis



Erythema in face

# Parasitic dermatitis

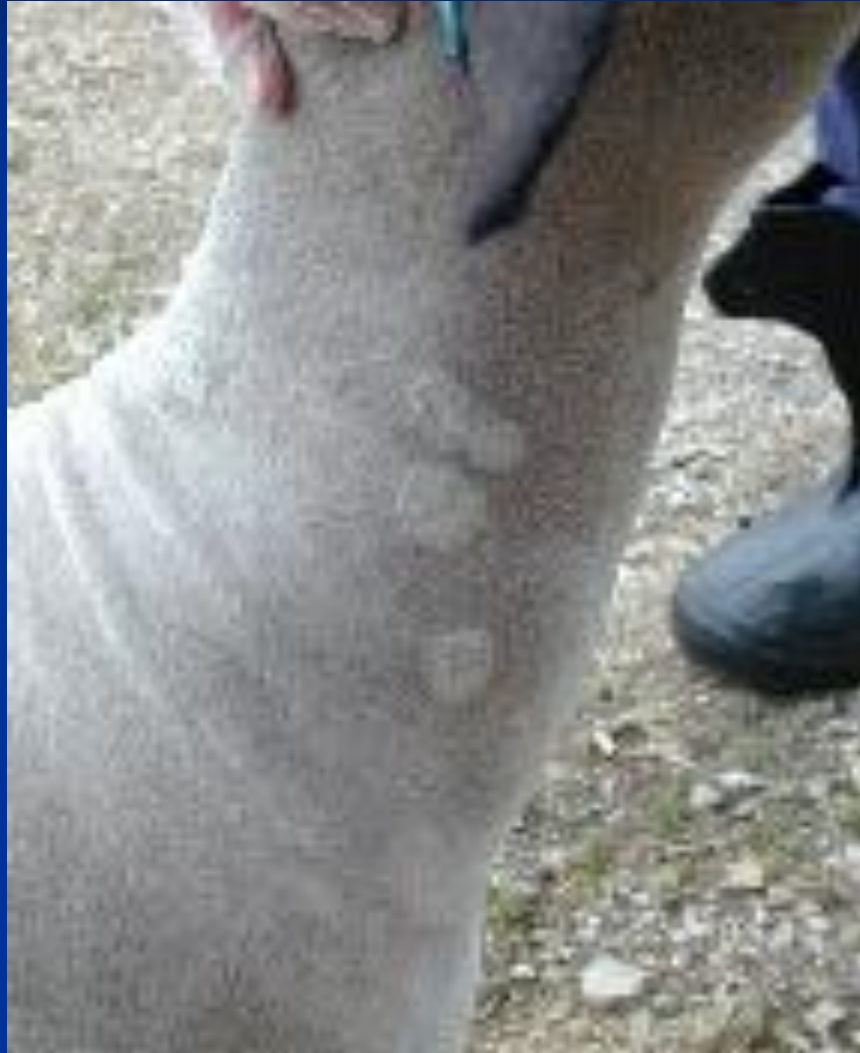

Mange lesion (parasitic dermatitis)



# Ringworm

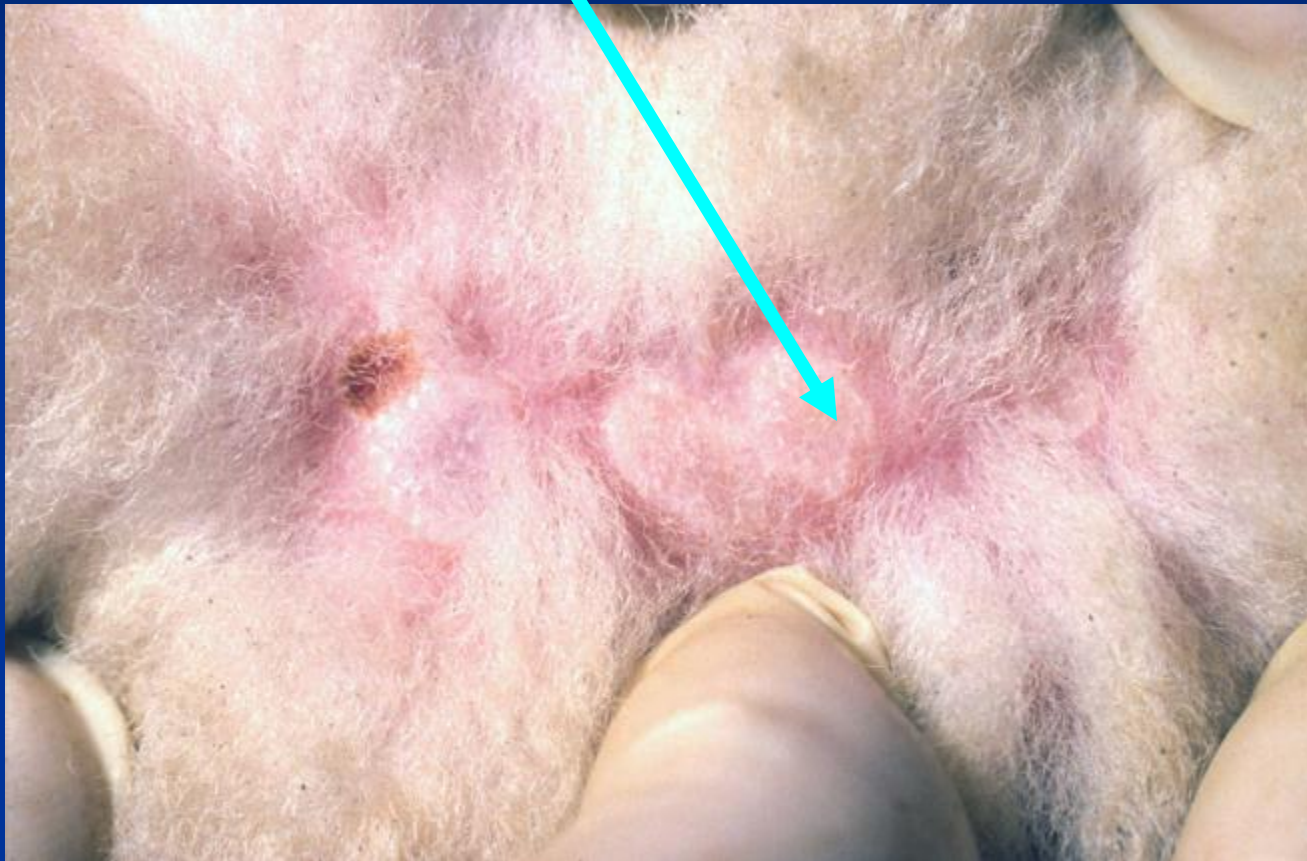# Ring worm

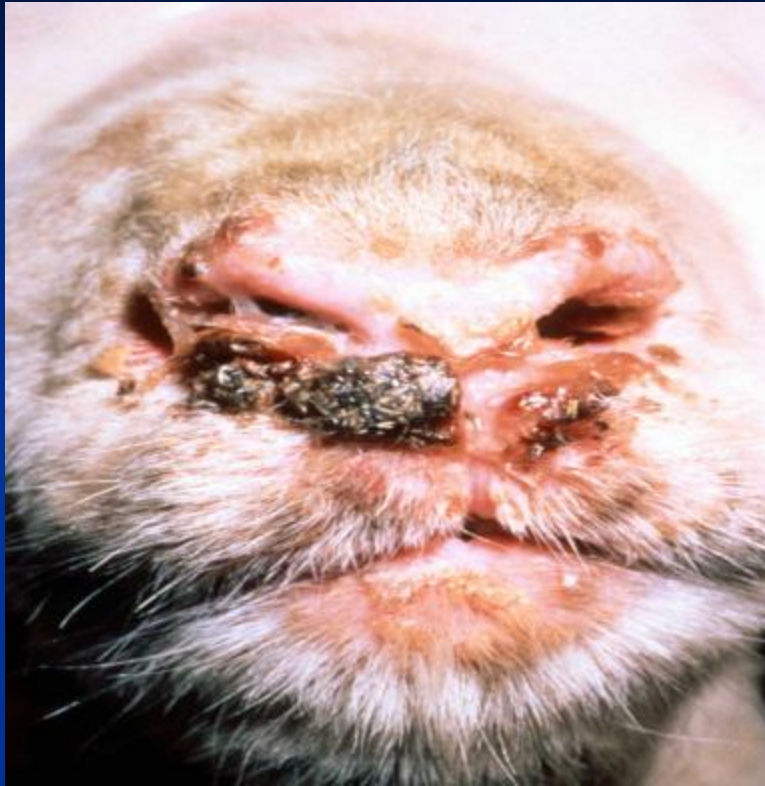

Compiled by Dr. Mohamed Ghanem



# Papules (Acne)





Pastular dermatitis  
(ORF)

# Rickets



# Phosphorus deficiency



# Rickets in a goat



# Knuckling over fetlock – copper deficiency

